



# Macular Morphology and Visual Acuity in Year Five of the Comparison of Age-related Macular Degeneration Treatments Trials

Glenn J. Jaffe, MD,<sup>1</sup> Gui-Shuang Ying, PhD,<sup>2</sup> Cynthia A. Toth, MD,<sup>1</sup> Ebenezer Daniel, MBBS, PhD,<sup>2</sup> Juan E. Grunwald, MD,<sup>2</sup> Daniel F. Martin, MD,<sup>3</sup> Maureen G. Maguire, PhD,<sup>2</sup> for the Comparison of Age-related Macular Degeneration Treatments Trials Research Group\*

**Purpose:** To evaluate associations of morphologic features with 5-year visual acuity (VA) in the Comparison of Age-related Macular Degeneration Treatments Trials (CATT).

**Design:** Cohort study within a randomized clinical trial.

**Participants:** Participants in CATT.

**Methods:** Eyes with age-related macular degeneration—associated choroidal neovascularization (CNV) and VA between 20/25 and 20/320 were eligible. Treatment was assigned randomly to ranibizumab or bevacizumab and to 3 dosing regimens for 2 years and was at the ophthalmologists' discretion thereafter.

**Main Outcome Measures:** Visual acuity, thickness and morphologic features on OCT, and lesion size and foveal composition on fundus photography (FP) and fluorescein angiography (FA).

**Results:** Visual acuity and image gradings were available for 523 of 914 participants (57%) alive at 5 years. At 5 years, 60% of eyes had intraretinal fluid (IRF), 38% had subretinal fluid (SRF), 36% had subretinal pigment epithelium (RPE) fluid, and 66% had subretinal hyper-reflective material (SHRM). Mean (standard deviation) foveal center thickness was 148  $\mu\text{m}$  (99) for retina, 5  $\mu\text{m}$  (21) for SRF, 125  $\mu\text{m}$  (107) for subretinal tissue complex, 11  $\mu\text{m}$  (33) for SHRM, and 103  $\mu\text{m}$  (95) for RPE + RPE elevation. The SHRM, thinner retina, greater CNV lesion area, and foveal center pathology (all  $P < 0.001$ ) and IRF ( $P < 0.05$ ) were independently associated with worse VA. Adjusted mean VA letters were 62 for no pathology in the foveal center; 61 for CNV, fluid, or hemorrhage; 65 for non-geographic atrophy (GA); 64 for nonfibrotic scar; 53 for GA; and 56 for fibrotic scar. Incidence or worsening of 8 pathologic features (foveal GA, foveal scar, foveal CNV, SHRM, foveal IRF, retinal thinning, CNV lesion area, and GA area) between years 2 and 5 was independently associated with greater loss of VA from years 2 to 5 and VA loss from baseline to year 5.

**Conclusions:** Associations between VA and morphologic features previously identified through year 1 were maintained or strengthened at year 5. New foveal scar, CNV, intraretinal fluid, SHRM and retinal thinning, development or worsening of foveal GA, and increased lesion size are important contributors to the VA decline from years 2 to 5. A significant need to develop therapies to address these adverse pathologic features remains. *Ophthalmology* 2019;126:252-260 © 2018 by the American Academy of Ophthalmology



Supplemental material available at [www.aaojournal.org](http://www.aaojournal.org).

During years 1 and 2 of the Comparison of Age-related Macular Degeneration Treatment Trials (CATT), anti-vascular endothelial growth factor (VEGF) therapy with ranibizumab (Lucentis; Genentech, South San Francisco, CA) or bevacizumab (Avastin; Genentech) resulted in rapid and sustained reduction in all types of retinal fluid and thickness, stabilization of lesion growth, reduction in vascular leakage, and an associated improvement in visual acuity (VA).<sup>1-4</sup> Intraretinal fluid (IRF), but not subretinal fluid (SRF) or subretinal pigment epithelium (RPE) fluid, was independently associated with worse VA. Very thin or very thick retinas, thick subretinal tissue, atrophy, and fibrotic scar were associated with worse VA.<sup>3,4</sup>

Participants continued to receive anti-VEGF therapy during the ensuing 3 years of CATT in a real-world treatment scenario whereby the participant's ophthalmologist chose the anti-VEGF agent and dosing frequency according to her/his best judgment. As we have recently reported, the average VA at the 5-year follow-up time point had declined from year 2 to a level that was below the baseline value at trial entry. Among eyes followed to 5 years, mean VA had improved from 62 to 70 letters by year 2 but had declined to 59 letters by year 5, representing an 11-letter loss.<sup>5</sup> Furthermore, other studies, including those from electronic medical record databases and from interventional trials, have demonstrated a decline in VA with long-term anti-VEGF therapy.<sup>6-8</sup> However, there are few data that address

directly the morphologic correlates to this VA decline and how this information could be applied in the clinic or in clinical trials. In the present report, we assessed the associations between macular morphology and VA during 5 years of anti-VEGF treatment, and we explored the retinal anatomic factors that contributed to the year 5 VA results in a real-world treatment setting.

## Methods

### Study Population

Details of the design and methods for CATT have been published.<sup>1,2</sup> A total of 1185 subjects were enrolled from 43 US clinical centers between February 2008 and December 2009. Only 1 eye per subject, the study eye, was treated as a part of the clinical trial. Inclusion criteria included subject age  $\geq 50$  years, presence of previously untreated active choroidal neovascularization (CNV) secondary to age-related macular degeneration in the study eye, and VA between 20/25 and 20/320. Choroidal neovascularization was considered active when leakage or increased stippling was seen on FA and intraretinal, subretinal, or sub-RPE fluid was documented on OCT. Choroidal neovascularization or its sequelae (i.e., pigment epithelium detachment, hemorrhage, blocked fluorescence, macular edema, or fluid) needed to involve the center of the fovea. For the CNV to be considered secondary to age-related macular degeneration, at least 1 druse  $>63 \mu\text{m}$  needed to be present in the study eye or fellow eye, or the fellow eye needed to have CNV or geographic atrophy (GA). Participants were initially assigned randomly with equal probability to 1 of 4 treatment groups in year 1: (1) ranibizumab monthly, (2) bevacizumab monthly, (3) ranibizumab as needed (pro re nata [PRN]), or (4) bevacizumab PRN. During the second year, participants in the monthly arms were re-randomized to continue on monthly treatment or switch to PRN therapy.<sup>2</sup> Participants were released from the study protocol after year 2 and were treated with anti-VEGF therapy (aflibercept, ranibizumab, or bevacizumab) at dosing intervals as determined by the treating physician's best judgment. They were recalled for an eye examination and ancillary image assessment at approximately 5 years ( $5.5 \pm 0.6$  years). Those participants who were assessed at this follow-up visit and their associated clinical data comprised the CATT follow-up study (CATT FS). For ease of description, in the following text, we refer to data collected in the CATT FS as the year 5 time point.

The institutional review boards associated with each center approved the study. All participants provided written informed consent. The study was performed in compliance with the Health Insurance Portability and Accountability Act.

### Study Procedures

**Follow-up Methods.** A detailed description of the methods used to enroll CATT FS subjects and the procedures performed at the year 5 visit have been described.<sup>5</sup> Briefly, all patients who enrolled in the clinical trial, except for those known to be deceased at 2 years, were targeted for participation in the CATT FS. Returning patients had a dilated eye examination, refraction and best-corrected VA measurement, OCT, color stereo fundus photography (FP), and fluorescein angiography (FA). All examinations were performed by study-certified personnel following the same protocols used during the clinical trial. OCT, FP, and FA were obtained at baseline and at prespecified intervals through year 2, at variable frequencies during years 2 to 5, and on all CATT FS participants, when possible, at year 5. Procedures used for the acquisition, analysis, and grading of OCT, FA, and color FP

images have been published.<sup>1,3</sup> Time-domain OCT images were obtained throughout year 1, and 22.6% of scans were obtained on spectral domain (SD) OCT in year 2 as has been reported.<sup>2</sup> All CATT FS OCT images were obtained with SD OCT.

### Data and Statistical Analysis

Only patients with a VA measurement between 53 months (4.4 years) and 83 months (6.9 years) after the date of treatment assignment in the clinical trial were included in the data analyses.

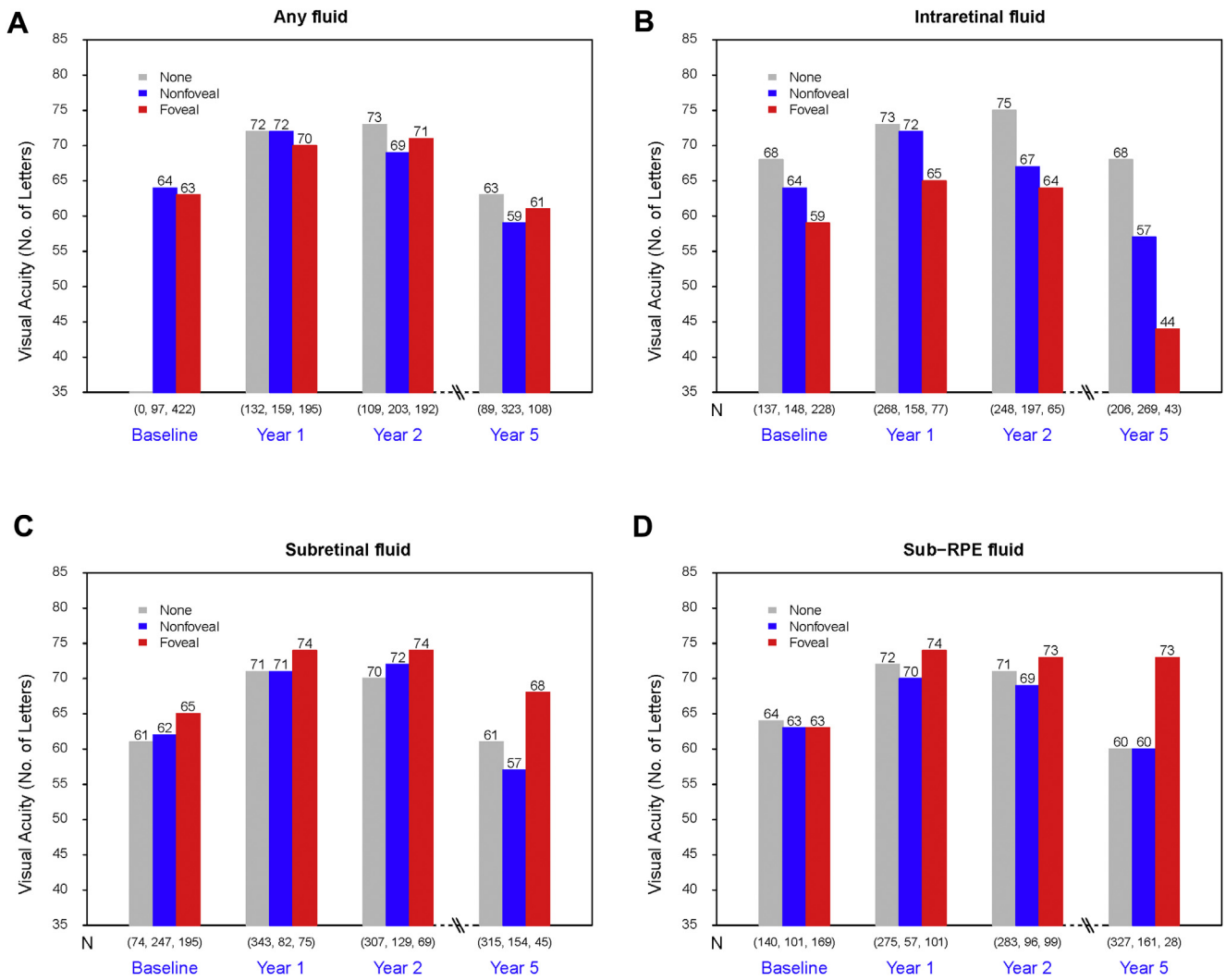
To evaluate the association of OCT thickness measurements with VA, thickness measurements were also divided into categories in the same way as in previous year 1 and year 2 reports.<sup>1,2</sup> To evaluate the association of each type of OCT fluid with VA, OCT fluid was categorized as one of the following: no fluid, extrafoveal fluid, and foveal-center fluid. The associations of OCT thickness and OCT fluid with VA were assessed using analysis of variance for any difference among the categories and linear trend *P* value for the ordered measurements. A post hoc analysis of all possible pairwise comparisons with adjustment for multiple comparisons was performed using the Hochberg procedure.<sup>9</sup>

The association of retinal morphology findings from FP, FA, or OCT with VA at year 5 and the association of morphologic change with VA change from years 2 to 5 were analyzed with multiple regression models. Backward variable selection processes were used by retaining only variables with *P* < 0.05 in the final multivariate model. All statistical analyses were performed in SAS version 9.2 (SAS Institute Inc., Cary, NC), and 2-sided *P* values < 0.05 were considered to be statistically significant.

## Results

### Association of Morphologic Features on OCT and Visual Acuity by Univariate Analysis

Morphologic and VA data were available on 523 patients in CATT FS and comprised the analysis population (Fig S1, Table S1, available at [www.aaojournal.org](http://www.aaojournal.org)). At 5 years, on OCT, 60% had IRF, 38% had SRF, 36% had subretinal pigment epithelium fluid (sub-RPEF), 66% had subretinal hyper-reflective material (SHRM), and 21% had outer retinal tubulations (ORTs). The mean (standard deviation) thickness was 279  $\mu\text{m}$  (160) for foveal center total thickness, 148  $\mu\text{m}$  (99) for retinal thickness, 5  $\mu\text{m}$  (21) for SRF, 125  $\mu\text{m}$  (107) for subretinal tissue complex, 11  $\mu\text{m}$  (33) for SHRM, and 103  $\mu\text{m}$  (95) for RPE + RPE elevation. Overall, the VA was slightly worse in eyes with macular fluid compared with those without, 63 vs. 59 and 61 letters for eyes without fluid or eyes with nonfoveal or foveal fluid, respectively (Fig 2A). However, mean VA differed depending on the specific type of fluid. As was seen at years 1 and 2, relative to the mean VA in eyes with no IRF (68 letters), mean VA was worse for eyes with extrafoveal IRF (57 letters; *P* < 0.001) and worse still for those with foveal IRF (44 letters; *P* < 0.001) (Fig 2B). In contrast, relative to the mean VA in eyes with extrafoveal SRF (57 letters), the mean VA was better for eyes with foveal SRF (68 letters, *P* = 0.02) and similar to those without SRF (61 letters) (Fig 2C). A trend toward better VA in eyes with foveal sub-RPEF had better mean VA (73 letters) than eyes without sub-RPEF (60 letters; *P* = 0.006) or those with extrafoveal sub-RPEF (60 letters; *P* = 0.01) (Fig 2D). As observed previously through year 2,<sup>10</sup> eyes with SHRM had worse mean VA, particularly if it involved the foveal center (41 letters for foveal SHRM, 63 letters for extrafoveal SHRM, and 72 letters for no SHRM; *P* < 0.001 for each pairwise comparison). Eyes with



**Figure 2.** Correlation of retinal fluid on OCT with visual acuity (VA). **A**, Visual acuity vs. any fluid. **B**, Visual acuity vs. intraretinal fluid (IRF). **C**, Visual acuity vs. subretinal fluid (SRF). **D**, Visual acuity vs. subretinal pigment epithelium (RPE) fluid.

ORT also had worse mean VA when compared with those without ORT (52 vs. 63 letters;  $P < 0.001$ ).

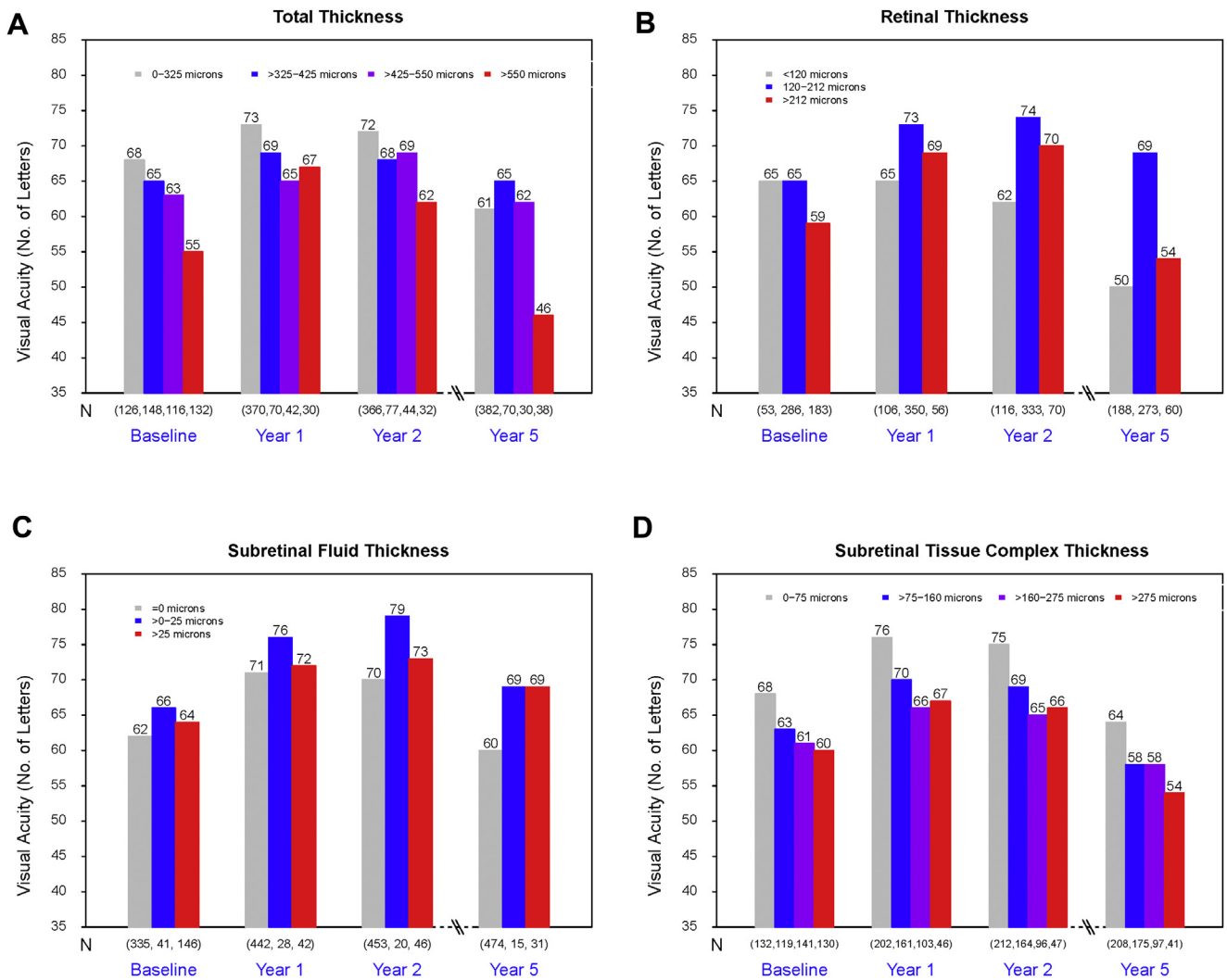
### Correlation of OCT-Determined Thickness Measurements with Visual Acuity by Univariate Analysis

At year 5, eyes with total thickness  $>550 \mu\text{m}$  had markedly worse mean VA (46 letters) than eyes with  $<550 \mu\text{m}$  (mean of 61–65 letters) (all  $P < 0.05$  when compared with the 3 other thickness groups) (Fig 3A, Table S1). The relationship between VA and retinal, SRF, subretinal tissue complex, and SHRM thickness was determined. As shown previously for CATT 1- and 2-year data, and prominently at year 5, eyes with very thin ( $<120 \mu\text{m}$ ; 50 letters) or thick retinas ( $>212 \mu\text{m}$ ; 54 letters) had worse mean VA than eyes with normal retinal thickness (120–212  $\mu\text{m}$ ; 69 letters; all  $P < 0.001$ ) (Fig 3B). When foveal SRF data were stratified by SRF thickness categories (0  $\mu\text{m}$ , 1–25  $\mu\text{m}$ , and  $>25 \mu\text{m}$ ), eyes with foveal SRF thickness  $>0 \mu\text{m}$  had better mean VA (69 letters) than eyes with SRF thickness of 0  $\mu\text{m}$  (60 letters) (Fig 3C), and eyes with foveal

SRF had better mean VA (68 letters) than eyes with no SRF (61 letters) or extrafoveal SRF (57 letters) (Table S1). Increasing thickness of the subretinal tissue complex was associated with increasingly worse mean VA (linear trend  $P = 0.002$ ) (Fig 3D).

### Correlation of Fundus Features Determined on Fluorescein Angiograms and Color Fundus Photographs with Visual Acuity on Univariate Analysis

At year 5, larger neovascular lesion area was associated with worse VA ( $P < 0.0001$ ) (Table S2, available at [www.aajournal.org](http://www.aajournal.org)). Eyes with lesion area  $5 \text{ mm}^2$  or less had a mean VA of 72 letters vs. 49 letters among eyes with lesion area  $>20 \text{ mm}^2$ . The presence and type of pathology in the foveal center as determined by FP and FA were associated with worse VA ( $P < 0.0001$ ) (Table S2). Eyes with no pathology in the foveal center had the best mean VA of 70 letters, whereas the mean for eyes with scar or GA was 46 letters.



**Figure 3.** Visual acuity with thickness measurements on OCT at baseline and years 1, 2, and 5. **A**, Visual acuity vs. total thickness. **B**, Visual acuity versus retinal thickness. **C**, Visual acuity vs. subretinal fluid (SRF) thickness. **D**, Visual acuity vs. subretinal tissue complex thickness.

### Multivariate Analysis of the Association between Visual Acuity and OCT and Fundus Features

The presence and foveal involvement of each of the 3 types of fluid on OCT, the thickness of each of the 3 retinal layers, the lesion size, and the foveal pathology were considered simultaneously in a multivariate linear regression model of VA, and a reduced, final model was determined by backward variable selection (Table 3). We found that the presence and foveal involvement of IRF and SHRM, retinal thickness, particularly <120 μm, larger total CNV lesion area, and the type of foveal pathology were all independently associated with worse VA at year 5. Of note, eyes with foveal GA or fibrotic scar had worse VA when compared with those without foveal pathology or those with non-GA, non-fibrotic scar, or CNV/fluid/hemorrhage (Table 3). This finding is notable given the large proportion of eyes at year 5 with foveal GA and fibrotic scar (Fig S4A–D, available at [www.aajournal.org](http://www.aajournal.org)). Foveal SRF was independently associated with better VA at CATT year 2.<sup>2</sup> In contrast, at year 5, although eyes with foveal SRF had better mean VA than those without

foveal SRF on univariate analysis, this relationship was not significant on multivariate analysis ( $P = 0.14$ ).

### Morphologic Associations with Visual Acuity Decline from Year 2 to Year 5

The mean VA declined approximately 2 Early Treatment Diabetic Retinopathy Study lines between year 2 and year 5 to a level below baseline.<sup>5</sup> Accordingly, we explored whether adverse pathologic features that developed or worsened from year 2 to year 5 accounted for the decline. We defined adverse features as those morphologic characteristics that developed or increased in size from year 2 to year 5 and that on multivariate analysis were statistically significantly associated with a 3-line (15 letters) VA worsening of VA. These adverse pathologic features included area of CNV lesion, area of GA, new foveal GA, new foveal scar, new foveal CNV, new SHRM within the center 1 mm, new foveal IRF, and new retinal thinning (Tables S4 and S5, available at [www.aajournal.org](http://www.aajournal.org)). Even among eyes that developed no adverse features, mean VA declined 3 letters (from 73 to 70 letters) from year 2 to year

Table 3. Multivariate Analysis for the Association of OCT and Fundus Photography Morphologic Features with Visual Acuity at Year 5 (N = 513)

OCT and Fundus Features at Year 5	N	Adjusted Mean (SE) VA Score in Letters at Year 5	P Value*
Total area of CNV lesion (mm <sup>2</sup> )			<0.001
≥0–≤5	112	67.8 (2.0)	
>5–≤10	109	62.5 (1.9)	
>10–≤20	114	61.5 (1.8)	
>20	91	55.6 (2.1)	
Unknown	87	53.5 (2.5)	
Foveal center pathology			<0.001
None	84	61.9 (2.3)	
Fibrotic scar	89	56.4 (2.2)	
GA	83	52.6 (2.2)	
Non-GA	120	65.1 (1.8)	
CNV or fluid, hemorrhage	53	61.4 (2.7)	
Nonfibrotic scar	26	63.6 (3.8)	
Other, CG/CD	58	66.0 (3.0)	
IRF present			0.045
No fluid	204	62.6 (1.4)	
Fluid not in foveal center	268	60.6 (1.2)	
Fluid in foveal center	41	51.6 (4.0)	
SHRM present			<0.001
No	176	66.0 (1.6)	
Yes, not at foveal center	207	63.7 (1.3)	
Yes, at foveal center	130	48.7 (1.9)	
Retinal thickness (μm)			<0.001
<120	184	54.2 (1.5)	
120–212	270	64.8 (1.2)	
>212	59	62.1 (3.2)	

CNV = choroidal neovascularization; GA = geographic atrophy; IRF = intraretinal fluid; RPE = retinal pigment epithelium; SE = standard error; SHRM = subretinal hyper-reflective material; VA = visual acuity.  
\*P values were from the multivariate regression models with all these morphologic variables in the same model.

5. However, when 2 or more adverse morphologic features developed, the mean decrease was approximately 3 lines, from 69 letters to 56 letters (Fig 5). In addition, the mean VA declined more between year 2 and year 5 when there were abnormal features, but the average VA at each time point was worse from year 1 to year 5, as the number of adverse features increased (Fig 6). Eyes that developed GA, scar, or CNV in the foveal center after year 2 had a mean loss greater than 3 lines between years 2 and 5, whereas eyes with foveal pathology already present at 2 years had a mean loss of 1 to 2 lines (Table S5). Eyes without foveal pathology at 5 years had a mean loss of approximately 1.5 lines.

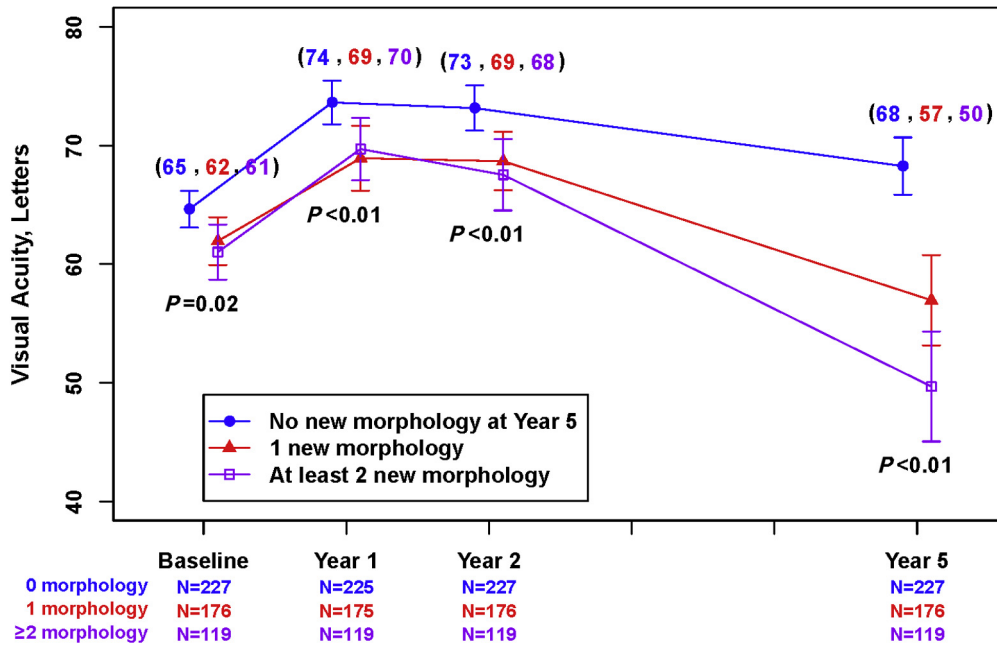
To better understand the effect of foveal GA and fibrosis on this VA decline, we calculated mean VA over time (baseline and years 1, 2, and 5) for eyes with and without GA or fibrosis by year 5, adjusting for all baseline predictors of scar and GA<sup>11,12</sup> in the multivariate analysis. As shown in Figure 7, although eyes with GA or fibrosis at year 5 had worse VA at baseline and years 1 and 2 compared with eyes without GA or scar by year 5, the VA difference at year 5 widened markedly, with adjusted mean VA of 49 letters in eyes with GA or fibrosis and 66 letters in eyes without this pathology.

## Discussion

During year 5 of this study, the strength of the year 1 and 2 associations between VA and morphologic features and quantitative measurements determined on OCT, FA, and FP were maintained or strengthened. In particular, IRF, SHRM, foveal GA and fibrotic scar, an abnormally thin or thick retina, larger CNV area, and increasing sub-RPE tissue complex thickness were associated with significantly worse VA, whereas eyes with SRF and sub-RPE fluid had better VA. Unlike years 1 and 2, when VA was improved or stabilized relative to baseline, VA tended to worsen to below baseline by year 5, coincident with an increased proportion of eyes with abnormally thin retinas, increased lesion size, GA, and subretinal fibrotic scar. Furthermore, the number of new adverse pathologic features from year 2 to year 5 was associated with worse VA throughout the study and a greater decrease in VA between year 2 and year 5.

A key 1- and 2-year study finding was that IRF, as determined by OCT, had a negative impact on VA at all time points examined. The strength of this association was even greater by year 5. When other potential confounding variables were controlled, foveal IRF was independently associated with worse VA over the entire study duration. The presence of other pathologic features, such as GA and fibrotic scar, did not worsen the negative impact of IRF on VA. The proportion of eyes with IRF, seen as round hyporeflective spaces on OCT, steadily increased from 45% at year 1, to 50% at year 2, and to 61% at year 5.<sup>5</sup> Despite the increased proportion of eyes with IRF, there was a higher proportion of eyes with retinal thinning (thickness <120 μm) at year 5 compared with those at years 1 and 2, 36% compared with 21% and 22% at years 1 and 2, respectively. We have previously speculated that some of the hyporeflective cystoid structures seen on OCT that persisted on anti-VEGF therapy were not fluid that leaked from CNV, but, rather, may have represented tissue loss mediated by non-VEGF-driven mechanisms, such as cell death. Our year 5 observations, that there were a higher proportion of eyes with hyporeflective cystic spaces, an increased percentage with abnormally thin retinas, and an even stronger negative correlation between IRF fluid and VA, when compared with preceding years, are consistent with this hypothesis.

Eyes with foveal SRF had better VA at year 5 than eyes that did not, an effect that was even more pronounced than it was at year 2. The reason for this association remains unclear, although it has been hypothesized that SRF could serve to protect the photoreceptors from potential toxicity related to direct contact with underlying diseased RPE. Furthermore, the SRF could be a biomarker for CNV that provides trophic support to the overlying retina. Alternatively, or perhaps in addition, the SRF might protect photoreceptors from direct infiltrative damage by serving as a fluid buffer between the outer segments and the CNV below it, or the SRF itself may contain neuroprotective substances. It is also conceivable that some of the eyes had associated central serous retinopathy, as part of a pachychoroid syndrome, which may have a better

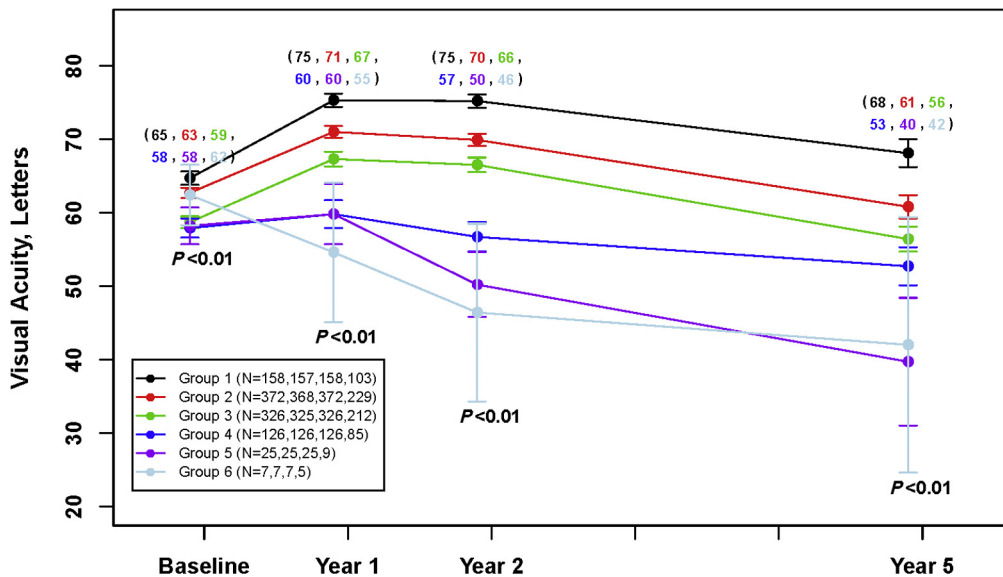


**Figure 5.** Mean visual acuity (VA) over time among eyes without morphologic features vs. eyes with at least 1 new adverse morphologic feature developed between years 2 and 5. The adverse features included the following: foveal geographic atrophy (GA); foveal scar, foveal choroidal neovascularization (CNV), subretinal hyper-reflective material (SHRM) at 1-mm center, foveal intraretinal fluid (IRF), and retinal thinning, each that developed after year 2; area of CNV lesion increased by >2 mm<sup>2</sup> between year 2 and year 5; change of GA area >2 mm<sup>2</sup> between year 2 and year 5.

VA outcome.<sup>13</sup> To this point, although it is beyond the scope of this article, we are currently evaluating the relationship between choroidal thickness and morphology in the eyes of CATT participants. The beneficial effect on VA disappeared when we adjusted for IRF, SHRM, and total CNV lesion size. These data indicate that SRF is associated

with at least 1 of these variables (IRF absence, SHRM absence, or small CNV size), so that once these factors are taken into account, there is no additional association between VA and SRF.

At year 5, in contrast to earlier time points, foveal sub-RPE fluid was associated with better VA on univariate analysis.



**Figure 6.** Mean visual acuity (VA) over time by groups of eyes defined on the basis of the number of new adverse morphologic features developed between years 2 and 5. The adverse features were the same as those described in Figure 5 and included foveal geographic atrophy (GA); foveal scar, foveal choroidal neovascularization (CNV), subretinal hyper-reflective material (SHRM) at 1-mm center, foveal intraretinal fluid (IRF), and retinal thinning, each that developed after year 2; area of CNV lesion increased by >2 mm<sup>2</sup> between years 2 and 5; change of GA area >2 mm<sup>2</sup> between years 2 and 5.

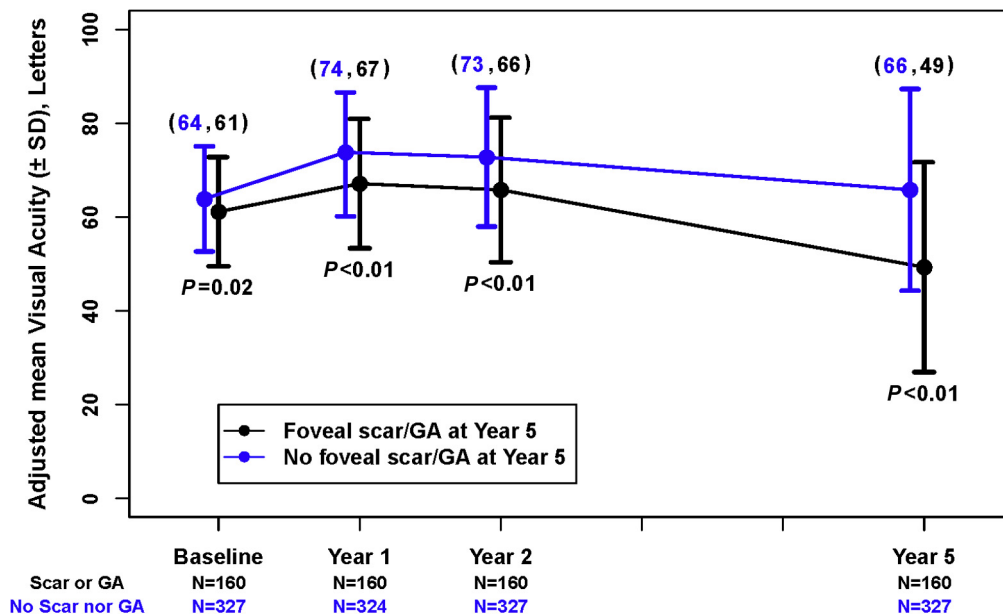


Figure 7. Visual acuity over time with and without foveal geographic atrophy (GA) and fibrosis.

The reason for better VA in these eyes, many whose sub-RPE fluid reflects a serous pigment epithelial detachment, is unclear. It is possible that in some eyes, sub-RPE fluid reflects type 1 CNV that provides trophic support to the retina. Regardless, one possible conclusion is that in the absence of other signs of active CNV, one may withhold anti-VEGF treatment if sub-RPE fluid does not change from one exam to the next. However, the study was not designed to determine the effect of withholding treatment in eyes with a particular fluid type, because the protocol mandated that all eyes were to be treated when IRF, SRF, or sub-RPE fluid was present. A randomized study to compare the effects of withholding anti-VEGF treatment when there is unchanged subretinal or sub-RPE fluid would be required to determine whether or not these types of persistent fluid should always be treated.

Foveal SHRM was independently associated with worse VA. In fact, this pathology was associated with the worst VA of all single parameters that were studied. Furthermore, when SHRM resolved by year 2, the VA was much better than when it persisted. We have previously shown that SHRM is associated with poor VA, probably because of overlying photoreceptor damage.<sup>10</sup> Subretinal hyperreflective material components typically include CNV, fibrin, fibrosis, blood, and fibrotic scar.<sup>10,11,14,15</sup> It is likely that fibrotic scar is the main SHRM component in these eyes with late-stage anti-VEGF-treated CNV lesions.<sup>14</sup> However, the study was not designed to correlate the specific location of fibrotic scar as determined by FA and FP, with SHRM, as assessed on SD OCT. To better address this point, our group has undertaken a study to register images obtained on SD OCT, with FP and FA images, so that we can correlate one-to-one the pathology observed on these modalities.

The VA worsened significantly from year 2 to year 5 when new adverse pathologic features developed, which

included foveal GA, fibrotic scar, CNV, SHRM within the central 1 mm, foveal IRF, retinal thinning, an increased CNV lesion size more than 5 mm<sup>2</sup>, or increased GA area >2 mm<sup>2</sup>. Furthermore, a greater number of these new adverse pathologic features were associated with worse VA at all time points from baseline and a greater VA decrease between year 2 and year 5, respectively. The presence of these adverse features goes a long way to explain why VA declined from year to year 5 of the study. Unfortunately, recent phase 3 combination therapy interventional studies designed to try to improve VA by targeting platelet-derived growth factor-related pathologies such as fibrosis and SHRM failed to meet their therapeutic end points.<sup>16</sup> Accordingly, there remains a significant unmet need to develop treatments that can limit scar formation and that can prevent GA development. Furthermore, our data to show progressive retinal thinning, ORT indicative of photoreceptor degeneration, and intraretinal hyporeflective cavitory spaces all point to an unmet need to develop neuroprotective strategies to accompany anti-VEGF treatment. Finally, the independent association of increased lesion size with worse VA highlights the need to develop treatments that limit lesion size and not just specific lesion components.

Although we have highlighted pathologic features that were associated with the VA decline from year 2 to year 5, these associations do not tell the whole story. Even among eyes without any adverse pathology at year 5, the VA still declined by 3 letters from year 2 to year 5. Clearly, there are factors that have not been identified to account for this observation. For example, synaptic reorganization associated with the underlying disease and lost neuroprotective effects induced by anti-VEGF therapy might play a role in the VA decline but may not have been detected by the imaging modalities used in this study.<sup>17</sup> Further

investigations that focus on reasons for the VA decline despite a lack of obvious pathology seen on OCT, FP, or FA are warranted.

In the present study, we conducted several novel analyses to determine anatomic correlates to VA decline with long-term anti-VEGF therapy. Expert readers evaluated images in a standardized manner to determine the impact of a variety of anatomic features on final VA and to assess the effect of change in morphologic features with change in VA over time, to help explain the VA decline from year 2 to year 5. Furthermore, we determined how the number of adverse anatomic features affected VA. Previous studies have examined anatomic factors that correlate with the final VA in an effort to explain the VA decline over time with long-term anti-VEGF therapy. For example, Gillies and colleagues<sup>6</sup> reported that fibrosis and atrophy, as reported by the treating ophthalmologist, might account for decreased VA after 7 years of anti-VEGF therapy. However, in CATT, we were able to delve more deeply into the causes of VA loss over time. Color photographs, fluorescein angiograms, and OCT scans were each analyzed at several time points, which allowed us to evaluate important morphologic characteristics such as lesion growth and lesion size, IRF, and SRF, and the relationship between changes in morphology with changes in VA and the relative contribution of the different morphologic features to VA changes. In contrast, the design of the study by Gillies and colleagues,<sup>6</sup> in which morphology and VA correlations depended on the treating ophthalmologists' reports, and which were obtained only at a single time point, precluded these types of analyses. In the Seven-Up study, anatomic features at final follow-up were also correlated with VA.<sup>7</sup> The area of macular atrophy as assessed on fundus autofluorescence images was associated with VA, but not subretinal fibrosis, as determined by FP. However, in that study, only a small number of subjects were studied (65 of 155 eligible subjects), and the study may have been underpowered to detect anatomic correlates such as subretinal fibrosis. Furthermore, the study only assessed VA morphologic correlates at the study end point but did not analyze changes in morphology to explain the decrease in VA that occurred after the initial VA improvement.

In conclusion, there has been much debate about whether retina specialists undertreat with anti-VEGF therapy in a real-world setting and whether undertreatment could account for the observed VA decline after 2 years of treatment in CATT and other studies.<sup>7,18,19</sup> There are undoubtedly some patients who do not receive sufficient anti-VEGF treatment, as evidenced by persistent VEGF-driven pathology, such as IRF, that we observed at years 2 and 5, and the slightly worse average VA (2.3 letters) seen at year 2 among eyes treated PRN when compared with those treated monthly. Alternative approaches to maximize physician practice efficiency and patient compliance, such as anti-VEGF sustained drug-delivery systems, would likely help in this regard. However, there are many patients who do receive aggressive treatment, and it is clear that undertreatment cannot and does not account for all of the VA decline that we observed between years 2 and 5. First,

during the first 2 years of CATT, a significant proportion of eyes developed visually adverse pathology, including foveal GA, fibrotic scar, retinal thinning, and lesion growth, despite monthly anti-VEGF treatment for 2 years, and the rate of GA was higher among eyes that received a greater number of injections.<sup>2,3</sup> Accordingly, more injections do not necessarily translate to prevention of VA loss in some cases. Second, there is no evidence that additional anti-VEGF therapy will prevent GA, and the development of GA or expansion from existing GA was a major contributor to VA decline between year 2 and year 5. Finally, there were a large number of eyes that retained excellent vision between year 2 and year 5 despite receiving no additional injections during that time. As such, the ideal number of anti-VEGF injections given over many years that will yield an optimal VA result is unknown and likely varies greatly among patients.

## References

1. CATT Research Group, Martin DF, Maguire MG, et al. Ranibizumab and bevacizumab for neovascular age-related macular degeneration. *N Engl J Med*. 2011;364:1897–1908.
2. Comparison of Age-related Macular Degeneration Treatments Trials Research Group, Martin DF, Maguire MG, et al. Ranibizumab and bevacizumab for treatment of neovascular age-related macular degeneration: two-year results. *Ophthalmology*. 2012;119:1388–1398.
3. Jaffe GJ, Martin DF, Toth CA, et al. Macular morphology and visual acuity in the comparison of age-related macular degeneration treatments trials. *Ophthalmology*. 2013;120:1860–1870.
4. Sharma S, Toth CA, Daniel E, et al. Macular morphology and visual acuity in the second year of the Comparison of Age-Related Macular Degeneration Treatments Trials. *Ophthalmology*. 2016;123:865–875.
5. Comparison of Age-related Macular Degeneration Treatments Trials Research Group, Maguire MG, Martin DF, et al. Five-year outcomes with anti-vascular endothelial growth factor treatment of neovascular age-related macular degeneration: the Comparison of Age-Related Macular Degeneration Treatments Trials. *Ophthalmology*. 2016;123:1751–1761.
6. Gillies MC, Campain A, Barthelmes D, et al. Long-term outcomes of treatment of neovascular age-related macular degeneration: data from an observational study. *Ophthalmology*. 2015;122:1837–1845.
7. Rofagha S, Bhisitkul RB, Boyer DS, et al; SEVEN-UP Study Group. Seven-year outcomes in ranibizumab-treated patients in ANCHOR, MARINA, and HORIZON: a multicenter cohort study (SEVEN-UP). *Ophthalmology*. 2013;120:2292–2299.
8. Writing Committee for the UK Age-Related Macular Degeneration EMR Users Group. The neovascular age-related macular degeneration database: multicenter study of 92 976 ranibizumab injections: report 1: visual acuity. *Ophthalmology*. 2014;121:1092–1101.
9. Hochberg Y, Benjamini Y. More powerful procedures for multiple significance testing. *Stat Med*. 1990;9:811–818.
10. Willoughby AS, Ying GS, Toth CA, et al. Subretinal hyper-reflective material in the Comparison of Age-Related Macular Degeneration Treatments Trials. *Ophthalmology*. 2015;122:1846–1853.e1845.
11. Daniel E, Toth CA, Grunwald JE, et al. Risk of scar in the comparison of age-related macular degeneration treatments trials. *Ophthalmology*. 2014;121:656–666.



12. Grunwald JE, Daniel E, Huang J, et al. Risk of geographic atrophy in the comparison of age-related macular degeneration treatments trials. *Ophthalmology*. 2014;121:150–161.
13. Manayath GJ, Shah VS, Saravanan VR, Narendran V. Polypoidal choroidal vasculopathy associated with central serous chorioretinopathy: pachychoroid spectrum of diseases. *Retina*. 2018;38:1195–1204.
14. Charafeddin W, Nittala MG, Oregon A, Sadda SR. Relationship between subretinal hyperreflective material reflectivity and volume in patients with neovascular age-related macular degeneration following anti-vascular endothelial growth factor treatment. *Ophthalmic Surg Lasers Imaging Retina*. 2015;46:523–530.
15. Shah VP, Shah SA, Mrejen S, Freund KB. Subretinal hyperreflective exudation associated with neovascular age-related macular degeneration. *Retina*. 2014;34:1281–1288.
16. Regeneron announces phase 2 study of aflibercept co-formulated with rinucumab (anti-pdgfr-beta) shows no benefit over aflibercept alone in neovascular age-related macular degeneration. 2016. <http://investor.regeneron.com/releaseDetail.cfm?releaseid=991601>. Accessed June 12, 2018.
17. Kurihara T, Westenskow PD, Bravo S, et al. Targeted deletion of Vegfa in adult mice induces vision loss. *J Clin Invest*. 2012;122:4213–4217.
18. Bhisitkul RB, Mendes TS, Rofagha S, et al. Macular atrophy progression and 7-year vision outcomes in subjects from the ANCHOR, MARINA, and HORIZON studies: the SEVEN-UP study. *Am J Ophthalmol*. 2015;159:915–924.e912.
19. Qin VL, Young J, Silva FQ, et al. Outcomes of patients with exudative age-related macular degeneration treated with anti-vascular endothelial growth factor therapy for three or more years: a review of current outcomes. *Retina*. 2018;38:1500–1508.

## Footnotes and Financial Disclosures

Originally received: April 7, 2018.

Final revision: August 14, 2018.

Accepted: August 27, 2018.

Available online: September 3, 2018. Manuscript no. 2018-817.

<sup>1</sup> Department of Ophthalmology, Duke University, Durham, North Carolina.

<sup>2</sup> Department of Ophthalmology, University of Pennsylvania, Philadelphia, Pennsylvania.

<sup>3</sup> Cole Eye Institute, Cleveland Clinic, Cleveland, Ohio.

Presented in part at: the Association for Research in Vision and Ophthalmology Meeting, May 4–8, 2016, Seattle, Washington.

\*See Appendix (available at [www.aaojournal.org](http://www.aaojournal.org)) for credit roster.

Financial Disclosure(s):

The author(s) made the following disclosure(s): G.J.J.: Consultant Heidelberg Engineering and Novartis.

C.A.T.: Royalties Alcon.

G.-S.Y.: Personal fees Chengdu Kanghong Biotech Co. Ltd., outside the submitted work.

M.G.M.: Personal fees Genentech/Roche.

Supported by Cooperative Agreements U10 EY017823, U10 EY017825, U10 EY017826, U10 EY017828, and U10 EY023530 from the National Eye Institute, National Institutes of Health, Department of Health and Human Services, Bethesda, Maryland. The funding organization participated in the design and conduct of the study and review of the manuscript. [ClinicalTrials.gov](http://ClinicalTrials.gov) number NCT00593450.

HUMAN SUBJECTS: Human subjects were included in this study. The institutional review boards associated with each center approved the study. All participants provided written informed consent. The study was

performed in compliance with the Health Insurance Portability and Accountability Act. All research adhered to the tenets of the Declaration of Helsinki.

No animal subjects were used in this study.

Author Contributions:

Conception and design: Jaffe, Ying, Toth, Daniel, Grunwald, Martin, Maguire

Data collection: Jaffe, Ying, Toth, Daniel, Grunwald, Martin, Maguire

Analysis and interpretation: Jaffe, Ying, Toth, Daniel, Grunwald, Martin, Maguire

Obtained funding: N/A

Overall responsibility: Jaffe, Ying, Toth, Daniel, Grunwald, Martin, Maguire

Abbreviations and Acronyms:

**CATT** = Comparison of Age-related Macular Degeneration Treatments Trials; **CATT FS** = Comparison of Age-related Macular Degeneration Treatments Trials follow-up study; **CNV** = choroidal neovascularization; **FA** = fluorescein angiography; **FP** = fundus photography; **GA** = geographic atrophy; **IRF** = intraretinal fluid; **ORT** = outer retinal tubulation; **PRN** = pro re nata; **RPE** = retinal pigment epithelium; **SD** = spectral domain; **SHRM** = subretinal hyper-reflective material; **SRF** = subretinal fluid; **sub-RPEF** = subretinal pigment epithelium fluid; **VA** = visual acuity; **VEGF** = vascular endothelial growth factor.

Correspondence:

Glenn J. Jaffe, MD, Department of Ophthalmology, Duke University, 2351 Erwin Rd., Box 3802, Durham, NC 27705. E-mail: [jaffe001@mc.duke.edu](mailto:jaffe001@mc.duke.edu).